

# Management of Precancerous Oral Lesions in Prosthetic Dentistry: A Clinical and Pathological Review

Rabab Sameer Kadhim

Department of Anesthesia Technologies, College of Health & Medical Technology, Sawa University, Almathana, Iraq

Email - [Rabab.samer@sawauniversity.edu.iq](mailto:Rabab.samer@sawauniversity.edu.iq)

Orchid ID - <https://orcid.org/0009-0004-3276-0925>

**Keywords:** Oral potentially malignant disorders, Leukoplakia, Prosthodontics, Oral cancer prevention, OSMF, Rehabilitation

**Received:**

**Revised:**

**Accepted:**



© 2026  
by the  
authors.

Submitted for possible open access publication under the terms and conditions of the

[Creative Commons Attribution \(CC BY\) license](https://creativecommons.org/licenses/by/4.0/).

## Abstract

Precancerous oral lesions, collectively referred to as oral potentially malignant disorders (OPMDs), represent a significant global health burden, particularly in developing countries like India. These lesions, including leukoplakia, erythroplakia, oral submucous fibrosis (OSMF), and lichen planus, demonstrate variable malignant transformation rates and significantly impact prosthetic rehabilitation outcomes. Prosthetic dentistry plays a crucial role not only in restoring function but also in monitoring and preventing disease progression. This review explores the clinical, pathological, and prosthetic management strategies for OPMDs, emphasizing early diagnosis, multidisciplinary intervention, and long-term surveillance. Recent advancements such as biomarker-based diagnostics, digital prosthodontics, and implant-supported rehabilitation are discussed. The integration of pathology and prosthetic considerations enhances treatment outcomes and quality of life. This review synthesizes current evidence to provide a comprehensive framework for clinicians.

Oral potentially malignant disorders (OPMDs) represent a heterogeneous group of lesions and conditions that carry a significant risk of progression to oral squamous cell carcinoma. These include leukoplakia, erythroplakia, oral submucous fibrosis (OSMF), and oral lichen planus, each characterized by distinct clinical and histopathological features. The global burden of these lesions is particularly pronounced in developing countries, where tobacco consumption, areca nut chewing, and alcohol use remain prevalent. In India, the incidence of OPMDs continues to rise, posing a substantial challenge to oral healthcare systems and necessitating early diagnosis and effective management strategies.

From a prosthodontic perspective, the presence of precancerous lesions introduces complexities in treatment planning and rehabilitation. Alterations in mucosal integrity, reduced tissue tolerance, and compromised oral function significantly influence prosthetic outcomes. Therefore, prosthetic dentistry plays a dual role—not only in restoring lost oral structures and functions but also in continuous monitoring for disease progression and recurrence.

This review aims to provide a comprehensive synthesis of the clinical presentation, pathological mechanisms, and multidisciplinary management of OPMDs, with a specific focus on prosthetic considerations. Emphasis is placed on the importance of early detection through clinical examination and adjunctive diagnostic tools such as biopsy, autofluorescence, and emerging molecular techniques. The review also highlights the role of

	<p>prosthodontists in minimizing mechanical trauma, designing patient-specific prostheses, and ensuring long-term follow-up.</p> <p>In addition, contemporary therapeutic approaches, including pharmacological interventions, laser therapy, and surgical excision, are critically evaluated in the context of prosthetic rehabilitation. Recent advancements such as digital prosthodontics, biomarker-based diagnostics, and artificial intelligence-assisted screening are explored as promising tools that can enhance diagnostic accuracy and treatment outcomes.</p> <p>Ultimately, successful management of precancerous oral lesions requires an integrated approach involving clinicians, pathologists, and prosthodontists. By bridging clinical and pathological insights with prosthetic rehabilitation strategies, it is possible to improve patient prognosis, prevent malignant transformation, and significantly enhance quality of life. This review provides a structured framework for clinicians aiming to deliver evidence-based and patient-centered care in the management of OPMDs.</p>
--	--

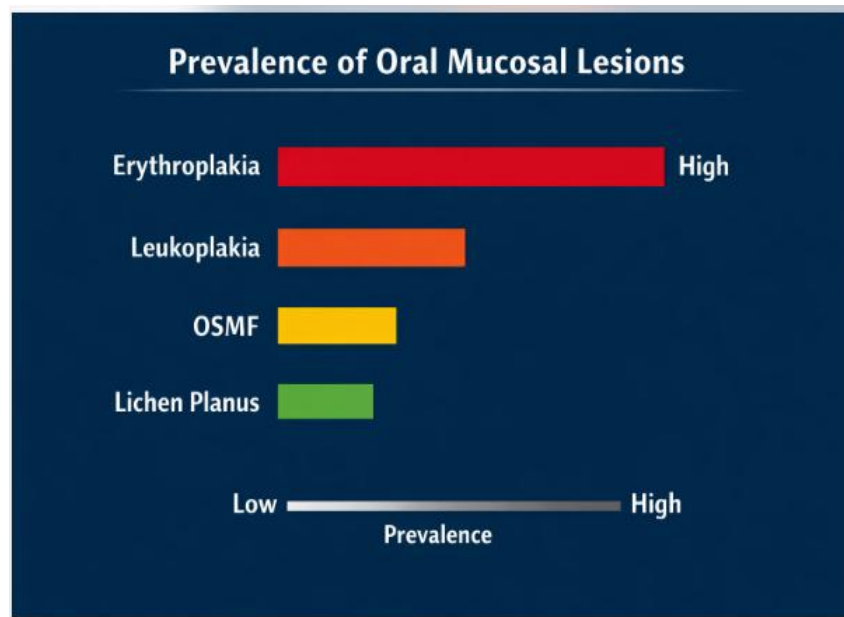
## 1. Introduction (Epidemiology and Significance)

Oral precancerous lesions are clinically identifiable mucosal abnormalities that possess a significant risk of malignant transformation. These include leukoplakia, erythroplakia, oral submucous fibrosis, and oral lichen planus. The burden of these lesions is particularly high in India, where lifestyle habits such as tobacco chewing and smoking are widespread. Epidemiological studies indicate that nearly **1% of the Indian population exhibits oral premalignant lesions**, with India contributing significantly to global oral cancer incidence. Globally, oral premalignant lesions affect approximately **1.5% to 4.5% of the population**, highlighting their public health importance.

The progression of these lesions to malignancy is variable, with transformation rates ranging from **0.13% to 2.9% annually**, depending on lesion type and risk factors. Leukoplakia, for instance, demonstrates a malignant transformation rate of up to **9.8%**, whereas erythroplakia carries an even higher risk. Such variability underscores the necessity for early detection and effective management.

**Table 1: Prevalence of Common Oral Precancerous Lesions in India**

Lesion Type	Prevalence (%)
Leukoplakia	4.3 - 6.7
OSMF	2.7 - 4.5
Erythroplakia	1.2 - 2.5
Lichen Planus	1.1 - 7.5



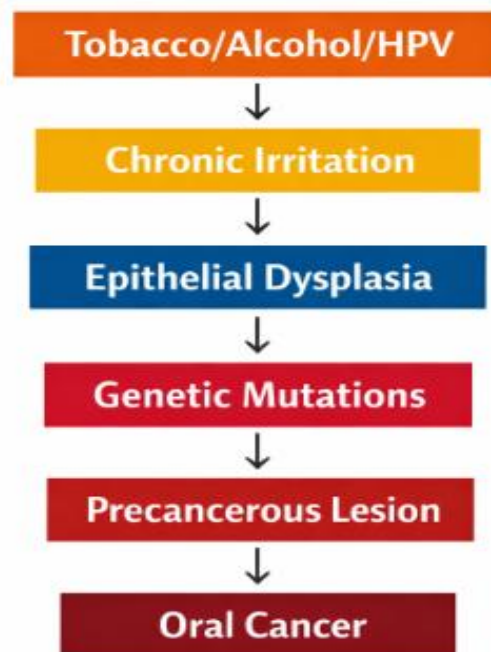
**Graph 1: Malignant Transformation Potential**

The prosthodontist often encounters such lesions during routine dental examinations. Early identification enables timely referral and intervention, preventing progression to oral cancer. Furthermore, prosthetic rehabilitation in such patients requires careful consideration due to compromised mucosal health, altered anatomy, and reduced tolerance to prostheses. Therefore, understanding epidemiology is essential for both prevention and rehabilitation planning.

## 2. Etiopathogenesis and Risk Factors

The development of oral precancerous lesions is multifactorial, involving environmental, behavioral, and genetic factors. Tobacco use remains the most significant etiological factor, with both smoked and smokeless forms contributing to mucosal alterations. Betel nut chewing, alcohol consumption, and nutritional deficiencies further exacerbate the risk. Studies indicate that **HPV infection is present in approximately 22.5% of oral premalignant disorders**, suggesting a viral component in pathogenesis.

Pathologically, chronic exposure to carcinogens leads to epithelial dysplasia characterized by cellular atypia, increased mitotic activity, and loss of normal tissue architecture. This dysplastic transformation progresses through stages, ultimately leading to carcinoma in situ and invasive cancer. The molecular mechanisms involve alterations in tumor suppressor genes (p53), oncogenes, and signaling pathways.



**Block Diagram: Pathogenesis of Oral Precancerous Lesions**

The role of prosthetic factors should not be overlooked. Ill-fitting dentures, sharp cusps, and chronic mechanical irritation can exacerbate mucosal changes. Prosthetic appliances may act as co-factors, accelerating dysplastic progression in susceptible individuals.

Additionally, systemic conditions such as immunosuppression and chronic diseases increase susceptibility. Socioeconomic factors and lack of awareness further contribute to delayed diagnosis. Therefore, etiopathogenesis is complex and requires a multidisciplinary approach involving dentists, pathologists, and oncologists.

**3. Clinical Features and Diagnosis**


Oral precancerous lesions present with diverse clinical manifestations, making diagnosis challenging. Leukoplakia appears as white plaques that cannot be scraped off, while erythroplakia presents as red velvety lesions with a higher malignant potential. Oral submucous fibrosis is characterized by progressive fibrosis, leading to restricted mouth opening, and lichen planus exhibits reticular or erosive patterns.

Early lesions are often asymptomatic, which contributes to delayed diagnosis. Clinical examination should include thorough inspection and palpation of all oral mucosal surfaces. Adjunctive diagnostic tools such as toluidine blue staining, autofluorescence, and brush biopsy aid in early detection.

**Table 2: Clinical Characteristics of Major Lesions**

Lesion	Appearance	Risk Level
Leukoplakia	White plaque	Moderate
Erythroplakia	Red lesion	High
OSMF	Fibrosis, trismus	Moderate - High
Lichen Planus Reticular/erosive		Low - Moderate

Histopathological examination remains the gold standard for diagnosis. Dysplasia grading (mild, moderate, severe) guides treatment planning. Advanced diagnostic methods such as bioimpedance analysis show promising results with **sensitivity of 95.9%**, improving early detection.



**Graph 2: Diagnostic Accuracy of Methods**

In prosthetic dentistry, diagnosis is crucial before initiating treatment. Any suspicious lesion must be evaluated and managed prior to prosthesis fabrication to avoid complications and ensure long-term success.

#### 4. Pathological Aspects and Malignant Transformation

The pathological progression of oral precancerous lesions involves a continuum from hyperkeratosis to epithelial dysplasia and carcinoma. Histologically, features such as nuclear pleomorphism, hyperchromatism, and abnormal mitotic figures are indicative of dysplasia. The severity of dysplasia correlates with the risk of malignant transformation.

Studies report that **oral potentially malignant disorders account for 17–35% of oral cancer cases**, emphasizing their clinical importance. Furthermore, transformation rates vary significantly, with leukoplakia showing rates between **3% and 50% depending on subtype**.

The pathological evolution of oral potentially malignant disorders (OPMDs) represents a dynamic continuum involving molecular, cellular, and tissue-level alterations. These changes begin with epithelial hyperplasia and hyperkeratosis and may progress to varying degrees of dysplasia before culminating in invasive carcinoma. The severity of epithelial dysplasia remains one of the most reliable predictors of malignant transformation, although it is not the sole determinant.

At the microscopic level, dysplastic epithelium demonstrates architectural and cytological abnormalities, including nuclear pleomorphism, increased nuclear-cytoplasmic ratio, hyperchromatism, and abnormal mitotic figures. Loss of basal cell polarity and disorganized epithelial stratification are also characteristic features. These alterations reflect underlying genetic mutations, particularly in tumor suppressor genes such as p53 and oncogenes that regulate cell proliferation and apoptosis.

**Table 3: Malignant Transformation Rates**

Lesion	Transformation Rate
Leukoplakia	3 - 10%
Erythroplakia	14 - 50%
OSMF	7 - 13%
Lichen Planus	<2%

The presence of risk factors such as age, alcohol consumption, and systemic diseases increases transformation risk. A cohort study demonstrated that patients with oral.

From a prosthodontic perspective, pathological changes influence tissue tolerance and healing capacity. Prosthetic rehabilitation must be planned considering these factors to prevent further irritation and disease progression.

Host factors such as age, immune status, and genetic predisposition significantly influence progression. Environmental exposures, particularly tobacco and alcohol, act synergistically to accelerate carcinogenesis. Chronic irritation from dental prostheses may further aggravate mucosal changes, emphasizing the need for careful prosthetic design.

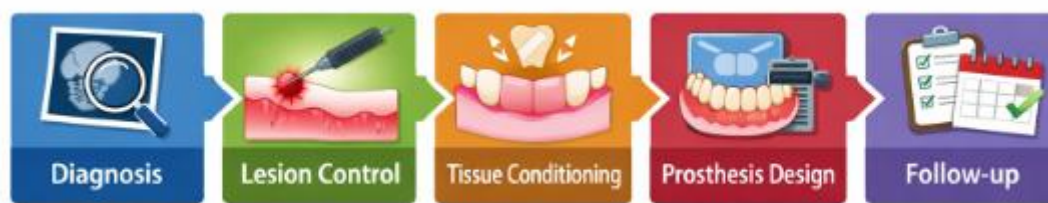From a clinical standpoint, identifying high-risk lesions is critical. Features such as ulceration, induration, and rapid growth warrant immediate biopsy. Histopathological grading, combined with clinical correlation, guides treatment decisions and follow-up intervals.

## 5. Prosthetic Considerations in Management

Prosthetic management of patients with precancerous lesions requires a cautious and individualized approach. The primary objective is to restore function while minimizing trauma to the mucosa. Removable prostheses should be designed with optimal fit, smooth surfaces, and minimal pressure areas. Soft liners may be used to enhance comfort.

Prosthetic rehabilitation in patients with precancerous oral lesions requires a highly individualized and cautious approach. The primary objective is to restore oral function while minimizing trauma to already compromised mucosal tissues. Unlike conventional prosthodontic cases, these patients present with altered tissue resilience, reduced salivary flow, and increased susceptibility to irritation.

One of the fundamental principles in prosthetic management is the elimination of mechanical irritants. Ill-fitting dentures, overextended flanges, and sharp occlusal contacts can exacerbate mucosal injury and potentially accelerate dysplastic changes. Therefore, meticulous attention must be given to impression techniques, border molding, and occlusal adjustments.



**Block Diagram: Prosthetic Management Approach**

Patients with OSMF often present with limited mouth opening, making prosthesis insertion challenging. Flexible dentures and sectional prostheses may be beneficial. Implant-supported prostheses should be considered cautiously due to compromised bone and soft tissue conditions.

**Table 4: Prosthetic Options**

Condition	Recommended Prosthesis
Leukoplakia	Conventional denture
OSMF	Flexible/Sectional denture
Post-excision	Obturator
High-risk lesions	Implant-supported (select cases)

Regular follow-up is essential to monitor lesion progression and prosthesis adaptation. Prosthodontists play a key role in early detection during recall visits.

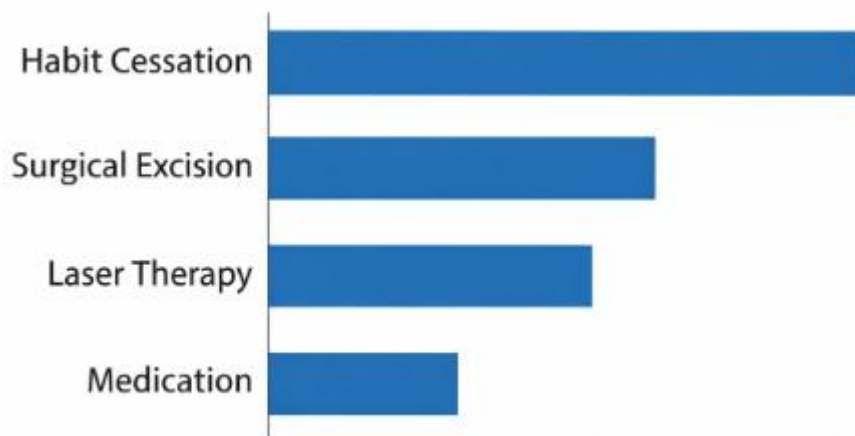
## 6. Medical and Surgical Management

Management of oral precancerous lesions involves elimination of risk factors, pharmacological therapy, and surgical intervention. Habit cessation remains the cornerstone of treatment. Pharmacological agents such as antioxidants, retinoids, and anti-inflammatory drugs are commonly used.

Surgical options include excision, laser ablation, and cryotherapy. Laser therapy is preferred due to minimal bleeding and better healing outcomes. Early intervention significantly reduces the risk of malignant transformation.

The management of oral precancerous lesions involves a combination of preventive, medical, and surgical approaches tailored to lesion severity and patient factors. The first and most critical step is the elimination of etiological factors, particularly tobacco and alcohol use. Behavioral counseling and cessation programs play a vital role in reducing disease progression.

Pharmacological therapy includes the use of antioxidants such as vitamins A, C, and E, as well as retinoids, which have shown efficacy in reducing lesion size and dysplasia. Anti-inflammatory agents and immunomodulators are also used in conditions like oral lichen planus.



**Graph 3: Treatment Effectiveness**

Prosthetic rehabilitation should be initiated after complete healing to avoid complications. Multidisciplinary collaboration ensures comprehensive care.

## 7. Recent Advances and Future Perspectives

Recent advancements in diagnostic and therapeutic modalities have improved the management of oral precancerous lesions. Molecular biomarkers, salivary diagnostics, and artificial intelligence-based screening tools are emerging as valuable tools.

Digital prosthodontics, including CAD/CAM technology, enables precise fabrication of prostheses, improving patient comfort and outcomes. Tissue engineering and regenerative therapies hold promise for future treatment.

The management of oral precancerous lesions has evolved significantly with advancements in diagnostic and therapeutic technologies. One of the most promising developments is the use of molecular biomarkers, which enable early detection at a cellular level before clinical changes become evident. Salivary diagnostics, in particular, offer a non-invasive and cost-effective screening tool.

Artificial intelligence (AI) is increasingly being integrated into oral healthcare. Machine learning algorithms can analyze clinical images and identify suspicious lesions with high accuracy, facilitating early intervention.

**Table 5: Emerging Technologies**

Technology	Application
AI-based screening	Early detection
Salivary biomarkers	Non-invasive diagnosis
CAD/CAM	Prosthesis fabrication
Bioimpedance	Lesion differentiation

These innovations are expected to enhance early diagnosis and improve survival rates.

## **8. Conclusion**

Management of precancerous oral lesions in prosthetic dentistry requires a comprehensive understanding of clinical, pathological, and rehabilitative aspects. Early detection, risk factor modification, and appropriate prosthetic design are essential for successful outcomes. Multidisciplinary collaboration and technological advancements are transforming patient care. Future research should focus on personalized treatment approaches and integration of advanced diagnostic tools.

The management of precancerous oral lesions within the domain of prosthetic dentistry represents a critical intersection between disease prevention and functional rehabilitation. Oral potentially malignant disorders are not merely localized mucosal abnormalities; rather, they are dynamic pathological entities with the potential to progress into life-threatening malignancies. Their early identification and effective management are therefore essential components of comprehensive oral healthcare.

This review highlights the importance of integrating clinical examination with pathological assessment to accurately diagnose and stratify the risk associated with various lesions. The variability in malignant transformation rates among different conditions underscores the need for individualized treatment planning and vigilant follow-up. Prosthodontists, often being the

first clinicians to encounter such lesions during routine examinations, play a pivotal role in early detection and timely referral.

Prosthetic rehabilitation in these patients requires a paradigm shift from conventional approaches. The presence of compromised mucosa, altered oral anatomy, and reduced tolerance necessitates the use of modified prosthetic designs that minimize trauma and enhance patient comfort. The incorporation of soft liners, flexible materials, and digital technologies has significantly improved treatment outcomes. However, the success of prosthetic interventions is closely linked to the control of underlying pathological conditions and patient compliance.

Medical and surgical management strategies must be tailored to the severity of the lesion and the overall health status of the patient. Habit cessation remains the cornerstone of therapy, while pharmacological and surgical interventions provide additional means to control disease progression. The timing and coordination of prosthetic rehabilitation following these treatments are crucial to ensure optimal healing and function.

The advent of advanced diagnostic tools, including molecular biomarkers and artificial intelligence, offers new avenues for early detection and risk assessment. These innovations, combined with digital prosthodontics, are poised to transform the management landscape of oral precancerous lesions. Future research focusing on personalized and precision-based approaches holds promise for further improving patient outcomes.

In conclusion, the effective management of precancerous oral lesions requires a multidisciplinary approach that integrates clinical expertise, pathological insights, and prosthetic innovation. By adopting a proactive and patient-centered strategy, clinicians can not only prevent malignant transformation but also restore function and improve quality of life. Continued advancements in research and technology will undoubtedly enhance our ability to diagnose, treat, and rehabilitate patients affected by these challenging conditions.

## References

1. Mahapatra M, Tripathi KP, Bhadouria TS, et al. Incidence progression and epidemiological study of oral precancerous lesions. *J Pharm Bioallied Sci.* 2025;17:S451–S453.
2. Kumbhalwar A, Shetiya SH, Kakodkar P, et al. Prevalence of precancerous lesions in India: A systematic review. *World J Methodol.* 2022;12(4):293–304.
3. Narasannavar AB, Angolkar M, Wantamutte A. Prevalence of oral precancerous lesions. *Asian Pac J Cancer Prev.* 2026;27(2):519–525.
4. WHO. Oral cancer: prevention and early detection. NCBI Bookshelf; 2015.
5. Gupta B, Johnson NW. Global epidemiology of oral leukoplakia. *BMC Oral Health.* 2023.
6. Warnakulasuriya S. Oral potentially malignant disorders: review. *J Oral Pathol Med.* 2020.
7. Speight PM, Khurram SA. Oral epithelial dysplasia. *Oral Surg Oral Med Oral Pathol.* 2018.
8. StatPearls. Premalignant lesions of oral mucosa. 2023.
9. Sapna S, Jain P, Sharma A. Prevalence of oral cancer and lesions. *JBIEvid Synth.* 2024.
10. Narasannavar AB. Community-based study of oral lesions. *APJCP.* 2026.

11. Arduino PG, Bagan J. Oral lichen planus and cancer risk. *Oral Dis.* 2019.
12. Frontiers Study Group. Oral lichen planus cohort study. *Front Oral Health.* 2025.
13. Gupta V, Goel P. Bioimpedance in oral lesions. 2024.
14. Amagasa T, Yamashiro M, Uzawa N. Oral premalignant lesions. *Int J Clin Oncol.* 2011.

---

**How to Cite:** Rabab Sameer Kadhim (2026). Management of Precancerous Oral Lesions in Prosthetic Dentistry: A Clinical and Pathological Review. *Global Journal of Forensic Pathology and Medicine*, 1(1), 36–46.  
<https://gifpm.com/index.php/gifpm>